

Increased bone turnover in focal areas of the skeleton in 2 phases:

- Lytic: ↑bone resorption and abnormal osteoclast activity.
- Sclerotic: rapid ↑bone formation by osteoblasts. However structure of this new bone is disorganised, weaker, less compact, more vascular, and liable to deformity/pathological #

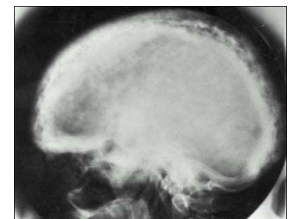
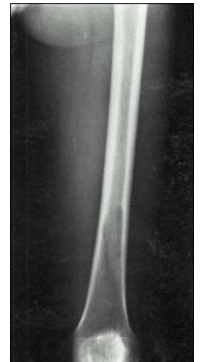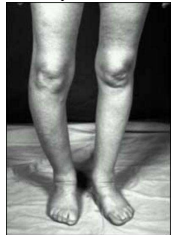N.B. Juvenile Paget's Disease is a rare and 'separate' disorder.

Epidemiology

- Uncommon - ~4% Caucasians >55y. M>F.
- ~15% familial or AD
- Controversially Paramyxovirus infection (including measles & RSV) cited as triggers

Features:

- Commonest in the axial skeleton, long bones, and the skull. The usual sites are the pelvis, lumbar spine, femur, skull and tibia.
- Commonly asymptomatic & discovered by elevated serum ALP or XR
- If symptomatic:
 - Common: Bone pain, Deformity (including sabre tibia, kyphosis, frontal bossing, an enlarged maxilla, an increase in head size), Pathological fractures, OA, Deafness and tinnitus (ossicles affected)
 - Less common: Spinal stenosis; Nerve compression
 - Rare: HyperCa (immobilisation), Hydrocephalus, High output cardiac failure, Paraplegia, Osteosarcoma (rare, 0.10-1.15%)



Investigations

Urine: Elevated hydroxyproline, deoxypyridinoline and N-telopeptide.

Bloods: Serial ALP↑↑ (bone specific), CMP (usually normal), PTH (normal)

Imaging: XR - osteolysis or excessive bone formation, classical V-shaped pattern between healthy and diseased long bones ("the blade of grass" lesion), multifocal sclerotic patches ("cotton wool") in skull. Osteosarcomas. Special: Radionuclide bone scans, bone biopsy if malignancy suspected.

Management

Non-drug treatment: Orthotic devices, sticks and walkers if legs affected.

Drug treatment

- NSAIDs and paracetamol may be effective for pain.
- Anti-resorptive therapy is with either bisphosphonates or rarely calcitonin.
 - Any Ca^{2+} and Vit D deficiency must be corrected before starting to avoid hypoCa
 - Osteonecrosis of the jaw has been reported

Surgery

- Bone deformity, osteoarthritis, pathological # and nerve compression may req surgery.
- Amputation may be necessary for osteosarcoma of long bones.

Prognosis

- This depends on the extent and degree of disease activity.
- Remission may be possible with successful treatment.
- Those who develop osteosarcoma have a very poor prognosis and most die within 3 years.