

General

Lesion possible locations: muscle, NMJ, nerve outside or inside brainstem

Conditions that can affect any CN: DM, MS, Tumours, Sarcoid, Vasculitis (e.g. PAN), SLE, Syphilis, chronic meningitis (tends to pick off lower CN one by one).

Olfactory (I) Nerve

- *Anatomy:* Olfactory cells are a series of bipolar neurones which pass through the cribriform plate to the olfactory bulb.
- *Signs:* Reduced taste and smell, but not to ammonia which stimulates the pain fibres carried in the trigeminal nerve.
- *Causes:* Trauma; frontal lobe tumour; meningitis.

Optic (II) Nerve

- *Anatomy:* The optic nerve fibres are the axons of the retinal ganglion cells. Fibres from the nasal parts of retina decussate at optic chiasm, join with the non-decussating fibres and pass back in optic tracts to visual cortex.
- *Signs and causes:*
 - Visual field defects:
 - Field defects start as small areas of visual loss (scotomas).
 - Monocular blindness: Lesions of one eye or optic nerve eg MS, giant cell arteritis.
 - Bilateral blindness: Methyl alcohol, tobacco amblyopia; neurosyphilis.
 - Bitemporal hemianopia: Optic chiasm compression eg internal carotid artery aneurysm, pituitary adenoma or craniopharyngioma
 - Homonymous hemianopia: Affects half the visual field contralateral to the lesion in each eye.
Lesions lie beyond the optic chiasm in the tracts, radiation or occipital cortex e.g. stroke, abscess, tumour.
 - Pupillary Abnormalities see pupillary abnormalities article.
 - Optic neuritis (pain on moving eye, loss of central vision, afferent pupillary defect, papilloedema). Causes: demyelination; rarely sinusitis, syphilis, collagen vascular disorders.
 - Optic atrophy (pale optic discs and reduced acuity): MS; frontal tumours; Friedreich's ataxia; retinitis pigmentosa; syphilis; glaucoma; Leber's optic atrophy; optic nerve compression.
 - Papilloedema (swollen discs):
 - Raised ICP (tumour, abscess, encephalitis, hydrocephalus, benign intracranial hypertension);
 - Retro-orbital lesion (e.g. cavernous sinus thrombosis);
 - Inflammation (e.g. optic neuritis);
 - Ischaemia (e.g. accelerated hypertension).

Oculomotor (III) Nerve

- *Anatomy* Emerges from brainstem on medial aspect of the crus cerebri and passes forwards between posterior cerebral and superior cerebellar arteries, very close to the

posterior communicating artery. It pierces the dura near the edge of the tentorium cerebelli, passes through the lateral part of the cavernous sinus with the IV and VI nerves to enter the orbit.

- *Signs* The initial sign is often a fixed dilated pupil which doesn't accommodate; then ptosis develops and then a complete internal ophthalmoplegia (masked by ptosis). Unopposed lateral rectus causes outward deviation of the eye. If the ocular sympathetic fibres are also affected behind the orbit, the pupil will be fixed but not dilated.
- *Causes of a single III lesion* DM; temporal arteritis; syphilis; posterior communicating artery aneurysm; idiopathic; ↑ICP if uncus herniation. If without a dilated pupil: DM or another vascular cause. Early dilatation of a pupil implies a compressive lesion. Diplopia from a third nerve lesion may cause nystagmus.

See also Combined cranial nerve lesions (below).

Trochlear (IV) Nerve

- *Anatomy* Passes backwards in the brainstem, decussates in the anterior medullary velum and emerges to pass round the cerebral peduncle between it and the temporal lobe, passing over the tentorium to enter the cavernous sinus with II and VI, and enters the orbit to supply the superior oblique.
- *Signs* Diplopia due to weakness of downward and outward eye movement. Commonest cause of a pure vertical diplopia. Patient tends to compensate by tilting head towards the unaffected side.
- *Causes of a single IV lesion* Rare and most commonly due to trauma to the orbit. May also occur in DM or infarction secondary to hypertension.

See also Combined cranial nerve lesions (below).

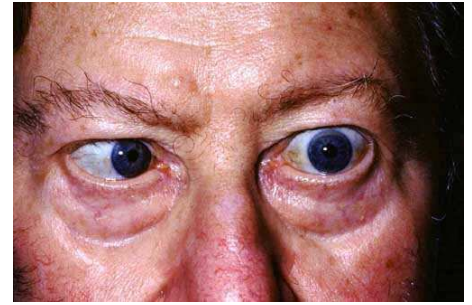Trigeminal (V) Nerve

- *Anatomy* Forms three trunks: ophthalmic, maxillary and mandibular divisions. The latter contains both sensory and motor fibres. There may be considerable individual variation in the exact areas of skin supplied.
 - Ophthalmic division lies with III, IV and VI in the cavernous sinus and supplies the skin over the medial nose, forehead, eye (including corneal reflex).
 - Maxillary division passes through the inferior part of the cavernous sinus and the foramen rotundum and joins with parasympathetic fibres to form the sphenopalatine ganglion (lacrimation). It then enters the orbit as the infraorbital nerve, eventually supplying the skin of the upper lip, cheek and triangle of skin extending from the angle of eye and mouth to an apex in the mid temporal region.
 - Mandibular division leaves the skull through the foramen ovale carrying sensory fibres from the skin of the lower lip and chin up to and including the tragus and upper part of the pinna; mucus membranes of floor of the mouth, cheek and anterior two-thirds of the tongue (taste fibres joining it from the chorda tympani branch of the facial nerve). Motor fibres supply the masseter, temporalis, pterigoids.
- *Signs* Reduced sensation or dysaesthesia over affected area. Weakness of jaw clenching and side to side movement. If there is a LMN lesion, the jaw deviates to the weak side when the mouth is opened. There may be fasciculation of temporalis and masseter.
- *Causes of a single V lesion* See also Combined cranial nerve lesions
 - *Sensory:* Trigeminal neuralgia, Herpes zoster, nasopharyngeal carcinoma.

- *Motor*: Bulbar palsy, acoustic neuroma.

Abducent (VI) Nerve

- *Anatomy* From the nucleus in the floor of the fourth ventricle fibres pass forward in the pons and emerge to follow a long extracerebral course on the base of the brain, across the apex of the petrous temporal, through the posterior fossa near the dorsum sellae to enter the cavernous sinus and thence to the orbit and lateral rectus.
- *Signs* Inability to look laterally. Eye is deviated medially because of unopposed action of medial rectus.
- *Causes of a single VI lesion* MS, pontine CVA. It is considered a false localizing sign (because of long extracerebral course) in raised ICP.



See also Combined cranial nerve lesions (below).

Facial (VII) Nerve

- *Anatomy* Mainly motor (some sensory fibres from external acoustic meatus, fibres controlling salivation and taste fibres from the anterior tongue). Fibres loop around the VI nucleus before leaving the pons medial to VIII and passing through the internal acoustic meatus. It passes through the petrous temporal in the facial canal, widens to form the geniculate ganglion (taste and salivation) on the medial side of the middle ear whence it turns sharply (and the chorda tympani leaves), to emerge through the stylomastoid foramen to supply the muscles of facial expression.
- *Signs* Facial weakness. In a LMN lesion the forehead is paralysed - the final common pathway to the muscles is destroyed; whereas the upper facial muscles are partially spared in an UMN lesion because of alternative pathways in the brainstem. There appear to be different pathways for voluntary and emotional movement. CVA's usually weaken voluntary movement often sparing involuntary movements (e.g. spontaneous smiling). The much rarer selective loss of emotional movement is called mimic paralysis and is usually due to a frontal or thalamic lesion.

Causes of a single VII lesion

- LMN: Bell's palsy, polio, otitis media, skull fracture, cerebello-pontine angle tumours, parotid tumours, Herpes zoster (Ramsay-Hunt syndrome), Lyme Disease
- UMN: (spares the forehead - bilateral innervation) Stroke, tumour.

See also Combined cranial nerve lesions (below).

Vestibulocochlear (VIII) Nerve

- *Anatomy* Carries two groups of fibres, those to the cochlea (hearing) and to the semicircular canals, utricle and saccule (balance and posture). They pass, together with the facial nerve, from the brainstem across the posterior fossa to the internal acoustic meatus.
- *Signs* Unilateral sensorineural deafness, tinnitus. Slow growing lesions seldom present with vestibular symptoms as compensation has time to occur.
- *Causes of a single VIII lesion* loud noise; Paget's disease; Ménière's disease; Herpes zoster; neurofibroma, acoustic neuroma, brainstem CVA; lead; aminoglycosides; furosemide (frusemide); aspirin. See also Combined cranial nerve lesions

Glossopharyngeal (IX) Nerve

- *Anatomy* Contains sensory, motor (stylopharyngeus only) and parasympathetic fibres (salivary glands). Passes across the posterior fossa, through the jugular foramen and into the neck supplying tonsil, palate and posterior third of tongue.
- *Signs* Unilateral lesions do not cause any deficit because of bilateral cortico-bulbar connections. Bilateral lesions result in pseudo-bulbar palsy. These nerves are closely interlinked.
- *Causes (single nerve lesions exceedingly rare)* Trauma, brainstem lesions, cerebello-pontine angle and neck tumours, polio, Gullain-Barre.

Vagus (X)

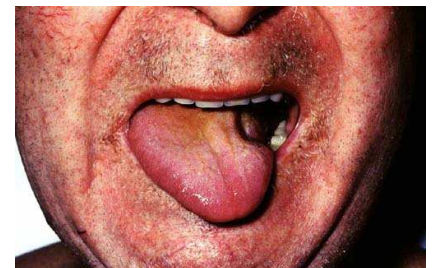
- *Anatomy* The vagus nerve, "the wanderer", contains motor fibres (to the palate and vocal cords), sensory components (posterior and floor of external acoustic meatus) and visceral afferent and efferent fibres. It leaves the skull through the jugular foramen, passes within the carotid sheath in the neck (giving off cardiac branches, and the recurrent laryngeal nerves supplying the vocal cords), through the thorax supplying lungs, and continues on via the oesophageal opening to supply the abdominal organs.
- *Signs* Palatal weakness can cause "nasal speech" and nasal regurgitation of food. The palate moves asymmetrically when the patient says "ah". Recurrent nerve palsy results in hoarseness, loss of volume and "bovine cough".
- *Causes (single nerve lesions exceedingly rare)* Trauma, brainstem lesions, tumours in the cerebello-pontine angle, jugular foramen and neck; polio, Gullain-Barre.

Spinal Accessory (XI)

- *Anatomy* Motor to sternocleidomastoid and trapezius.
- *Signs* weakness and wasting of these muscles.
- *Causes* as vagus above.

Hypoglossal (XII)

- *Anatomy* It passes briefly across the posterior fossa, leaves the skull through the hypoglossal canal and supplies motor fibres to the tongue and most of the infrahyoid muscles.
- *Signs* A LMN lesion produces wasting of the ipsilateral side of the tongue, with fasciculation; and on attempted protrusion tongue deviates towards affected side, but the tongue deviates away from the side of a central lesion.
- *Causes of a single XII lesion:* Rare. Polio, syringomyelia TB, median branch thrombosis of the vertebral artery.



Combined cranial nerve lesions

- *VII, VIII, then V and sometimes IX:* cerebellopontine angle tumours.
- *V, VI (Gradenigo's syndrome):* lesions within the petrous temporal bone.
- *Combined III, IV, VI:* stroke, tumours, Wernicke's encephalopathy, aneurysms, MS, myasthenia gravis, meningitis, muscular dystrophy, myotonic dystrophy, cavernous sinus thrombosis, Guillain-Barre, cranial arteritis, trauma and orbital pathology.